

Case

Presented by:

Marie A. de Perio, M.D.
IDSA 2007

HPI: 40 yo M from Central America presented with a 2 month history of hemoptysis. He reported red blood mixed with yellow sputum. Also noted dyspnea on exertion and diffuse pleuritic chest pain. He complained of night sweats, decreased appetite and weight loss.

Denied fevers or chills. Denied any other sites of bleeding. Denied sick contacts, including anyone with tuberculosis.

PMH: None

Meds: None

SH: Emigrated to the U.S. from Central America 2 years ago. Remote history of smoking. Denied drug or alcohol use.

PE: T: 99.8°F, BP: 120/52, HR: 62, RR: 18, O₂ saturation: 90% on 2L.

Pleasant, cachectic male, no distress.

HEENT: within normal limits, no oral lesions.

Chest: Crackles at left base. Remainder of exam normal.

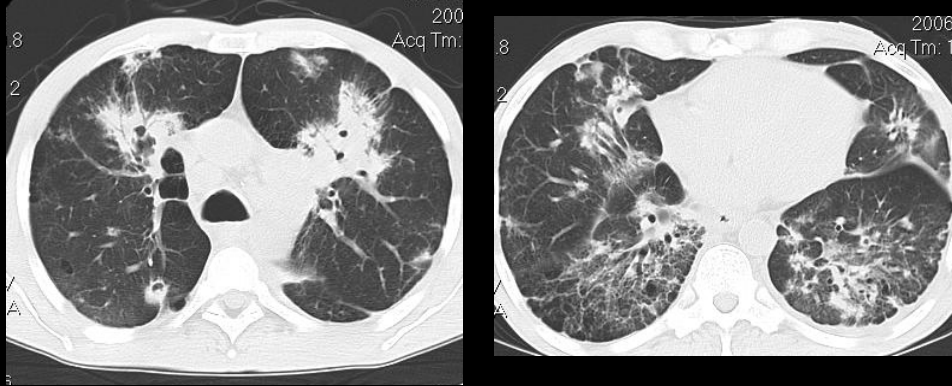
Studies: WBC 14.6 (80%P). Hb 12.6. Platelets 502. Chemistries & LFTs: normal.

Sputum gram stain: many PMN & mononuclear cells, no organisms.

Sputum AFB smear negative x 3

HIV ELISA: negative

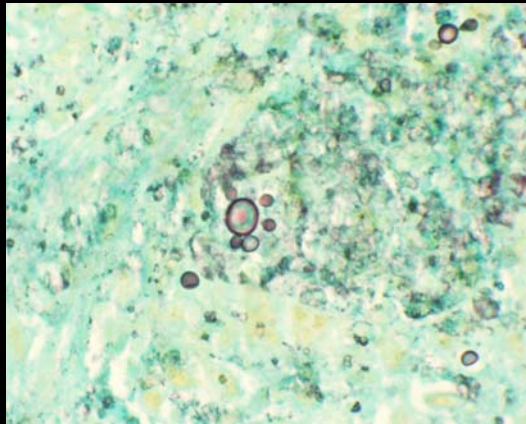
Chest imaging



Multiple scattered nodular opacities w/ cavitary lesions
Extensive mediastinal and hilar LAD
Irregular foci of airspace disease, especially in BLL

Diagnostic testing

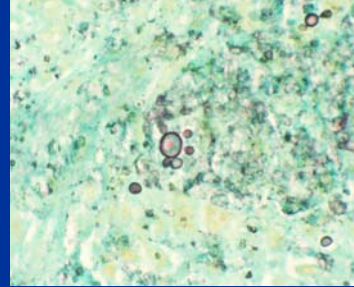
- Patient underwent bronchoscopy with BAL and biopsy. Stains from tissue revealed:



Lung, GMS stain, 40X (Courtesy of Judith Rhodes, PhD)

Differential Diagnosis

1. *Histoplasma capsulatum*
2. *Blastomyces dermatidis*
3. *Cryptococcus neoformans*
4. *Paracoccidioides brasiliensis*
5. *Pneumocystis jiroveci*

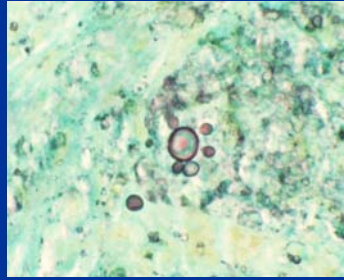


Diagnosis and Follow-up

- Biopsy revealed acute and chronic inflammation, with poorly-formed granulomas. AFB stain negative. Fungal organisms were seen that were morphologically consistent with *Paracoccidioides*.
- 6 weeks later, the fungal culture grew *Paracoccidioides brasiliensis*.
- He was treated with oral itraconazole, with clinical improvement: the hemoptysis and dyspnea resolved, his appetite improved and he went back to work.

Paracoccidioides brasiliensis

- Dimorphic fungus
- Multiple sporulation of small buddings covering whole surface of the mother cell
- Steering wheel appearance=
PATHOGNOMONIC



Paracoccidioidomycosis

- Endemic in Latin America, between Mexico 20°N and Argentina 35°S
- Most published cases from Brazil, Venezuela, Colombia
- Not described in the Caribbean or Chile

Paracoccidioidomycosis: Clinical aspects

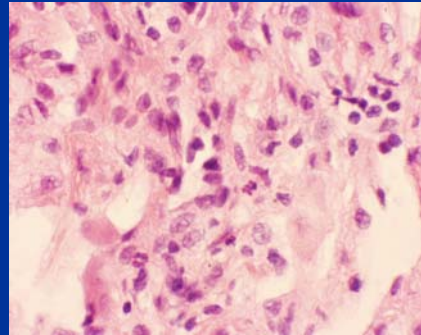
- Adult, chronic progressive form
 - Reactivation of quiescent lung lesions
 - Fever is rare
 - Symptoms include: weight loss, malaise, cough, eventually hemoptysis
 - May be misdiagnosed as TB (which can coexist)

Paracoccidioidomycosis: Clinical aspects (Continued)

- Adult disseminated form
 - Multifocal dissemination to skin, oral mucosa, tongue, palate, vocal cords
 - Skin lesions (25%): hyperkeratotic plaques or ulcerative crusted lesions
 - Cervical, axillary, mediastinal lymphadenopathy
 - Adrenal insufficiency (15%)
 - Can also involve spleen, liver, male GU tract, vascular system

Paracoccidioidomycosis: Diagnosis

- Visualization by direct microscopy (GMS, H&E stains)
- Isolation in culture can take >1 month
- Must be handled inside biohazard safety hood



Lung, H&E stain, 40X
(Courtesy of Judith Rhodes, PhD)

Final Diagnosis

Paracoccidioidomycosis of the lung

Contributor:

Marie A. de Perio, M.D.

